

TECHNIQUE CLINIC

Jumbo Separators for Partial Molar Impactions

Partial impactions of erupting permanent molars do not occur often, but when they do, they can cause long-term problems such as disruption of the occlusal plane, damage to abutment teeth, and creation of food traps with subsequent tooth decay and periodontal problems. A sequence of elastic separators can be used to resolve many of these impactions efficiently and effectively, with minimal patient discomfort.

Conventional elastomeric ring separators come in two sizes: green—3mm diameter, .75mm thick; and blue—4mm diameter, 1mm thick (Fig. 1). These are easy to fit and effective

at moving teeth apart as much as 1mm.

What I call “jumbo separators”—larger and thicker, black rubber “O” rings, 6mm diameter and 2mm thick—can be purchased from rubber outlets or hydraulic supply companies.* These can be sterilized in the same way as with standard separators. The jumbo separators should be soaked in hot water for two to three minutes prior to fitting. This makes them more pliable and less susceptible to fracture.

The standard separator pliers tend to overstretch and partially deactivate the separators (Fig. 2). Although this is not a problem in routine use, maximum activation is required to upright impacted molars. In such cases, therefore, the separators

should be placed with a pair of fine, slim-line needle holders. Stretching the separator by no more than one-third of its diameter allows easy placement with little distortion and deactivation.

When used in sequence with the smaller orthodontic separators, the jumbo separators can move teeth apart as much as 2mm, which is often enough to free partially impacted molars.

Case 1

A 9-year-old female presented with an upper left first molar partially impacted into the distal surface of the second deciduous molar (Fig. 3). Because patients this young do not fully comprehend the need to correct such impactions, treatment needs to be gentle and, where



Fig. 1 Separators: green (standard), 3mm diameter × .75mm thick; blue (standard), 4mm diameter × 1mm thick; black (jumbo), 6mm diameter × 2mm thick.




Fig. 2 A. Standard separator plier overstressing blue separator. B. Excessively stretched blue separator. C. Unused blue separator. D. Blue separator previously stretched with fine, slim-line needle holders. E. Black jumbo separator stretched with needle holders by no more than one-third of diameter to allow placement with minimal deactivation.

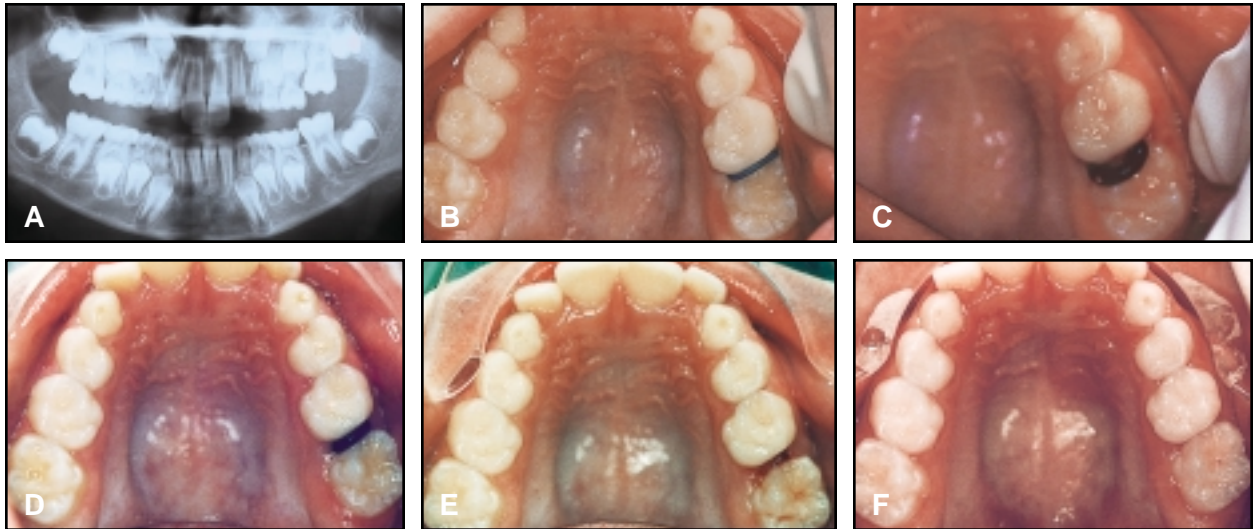


Fig. 3 Case 1. A. 9-year-old female patient with partially impacted upper left first molar. B. Placement of blue separator. C. Placement of jumbo separator one week later. D. Jumbo separator two months later. E. After removal of jumbo separator. F. Six weeks after separation.

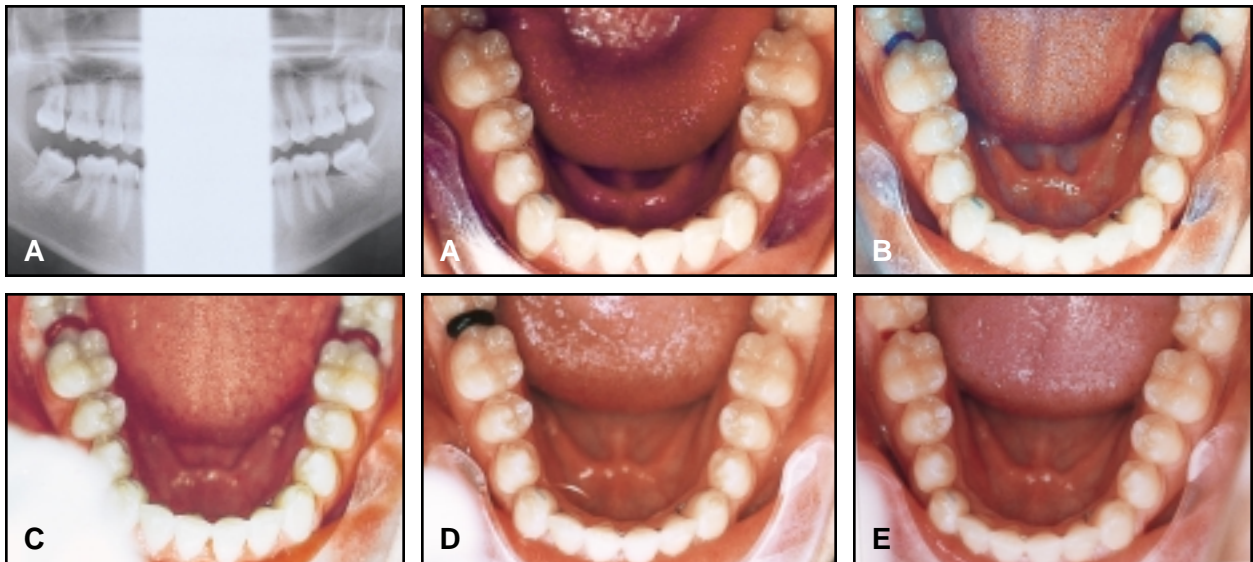


Fig. 4 Case 2. A. 19-year-old male patient with partially impacted lower third molars. B. Placement of blue separators. C. Placement of jumbo separators one week later. D. Jumbo separator after two months (lower left separator was dislodged a week earlier). E. Third molars in place after removal of jumbo separator.

possible, to involve minimum patient cooperation. Patients are asked to continue routine tooth-brushing, but not to floss or use toothpicks around the separators.

In this case, a blue separator was fitted in about one minute, using slim-line needle holders, and left in place for one week. The blue separator was then replaced with a jumbo separator, requiring less than two minutes of chairtime. The black separator was left in place for two months to allow stabilization of the correction. Patient discomfort was minimal during this treatment.

A review six weeks later confirmed that the impaction had not relapsed.

Case 2

A 19-year-old male patient had previously undergone orthodontic treatment involving the removal of all second permanent

molars. The lower third molars erupted with a mesial tilt and became partially impacted into the distal surfaces of the first permanent molars (Fig. 4).

Blue separators were placed for one week, then replaced with jumbo separators for another two months. Total chairtime was less than 10 minutes, and the patient experienced little discomfort.

Conclusion

Advantages of this serial separation technique include:

- Inexpensive materials that are easy to install and remove.
- Minimal chairtime.
- Only minor patient discomfort from fitting and wearing of the separators.
- No need for special patient cooperation.
- Minimal risk of harm if the separators fall out and are swallowed.



ROBERT CERNY, BDS, MDS
6/115 Darby St.
Newcastle
New South Wales 2300
Australia